

# Defecografie

Een 'gat' in de markt.....

# Defecografie



Tjeerd Wiersma

Radioloog

Rijnstate, Arnhem

# Defecografie

Dynamic Rectal Examination  
(DRE)

# Dynamic Rectal Examination DRE

## Uitvoering en interpretatie

- Belangenverstrengeling: geen

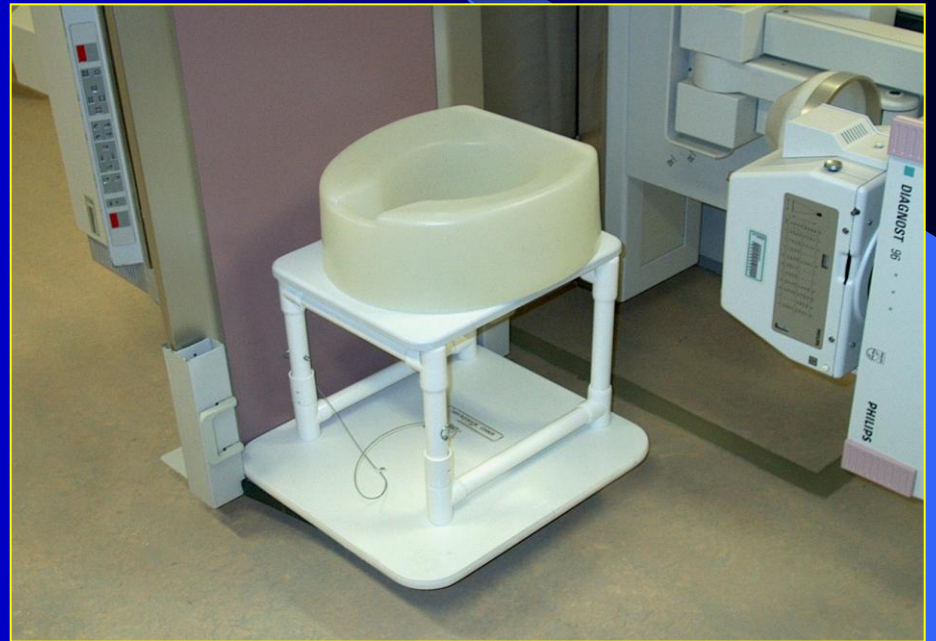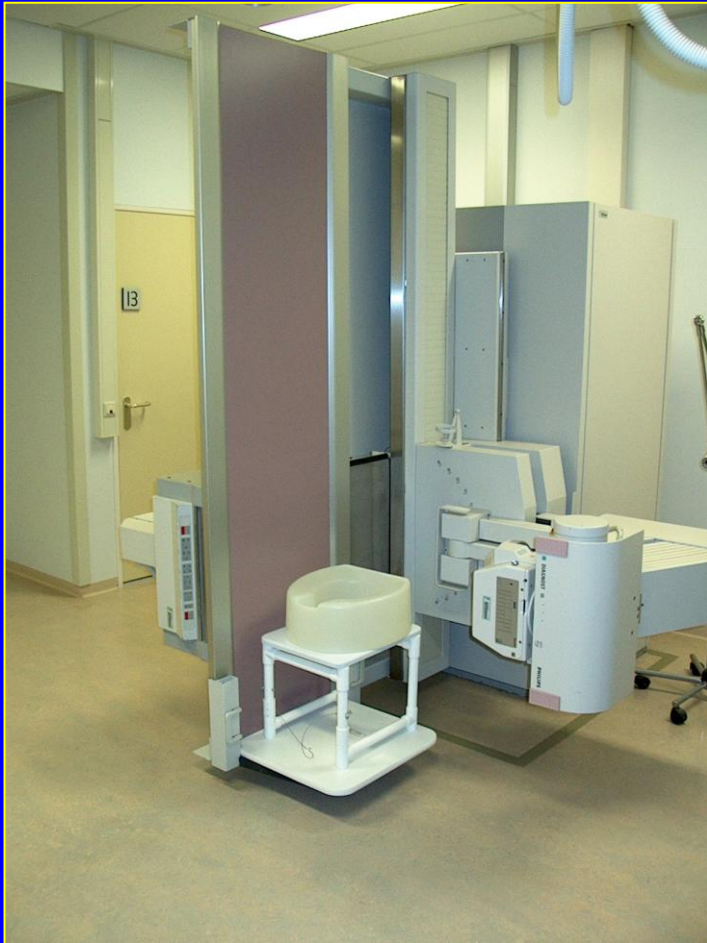# Uitvoering onderzoek

- telecommand statief
- beeldregistratie: dynamic fluo-grab  
(video registratie)

# Uitvoering onderzoek

- geen laxatie (rectum is normaal leeg)
- lege blaas
- contrast: oraal
  - rectaal
  - vaginaal

# Brunswick Chair



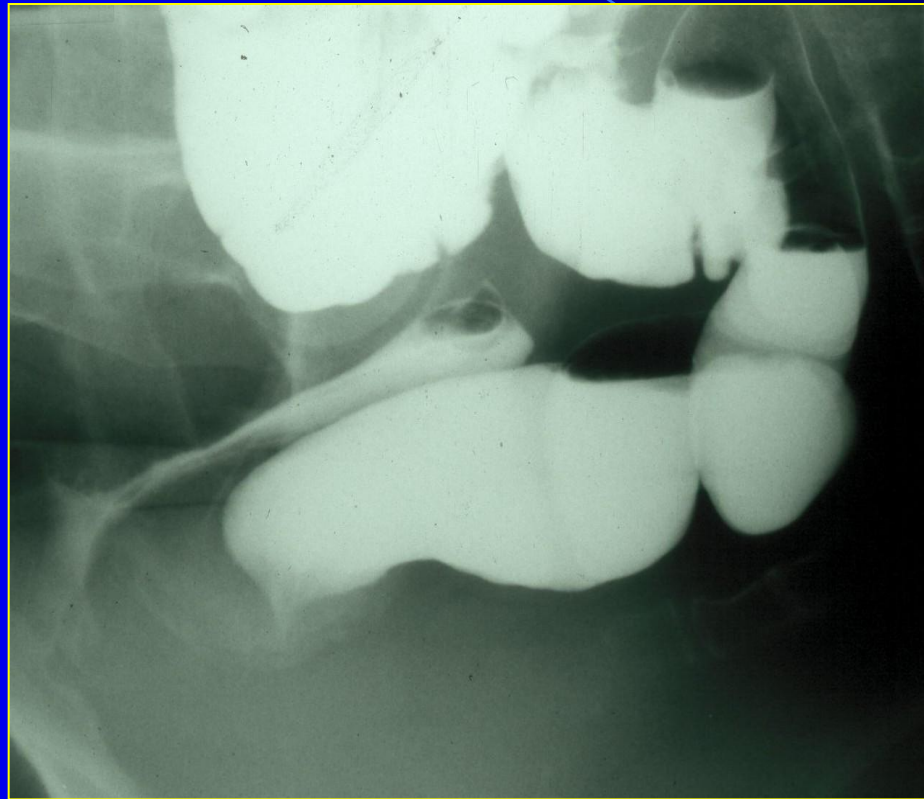


# In 't begin..... 1991



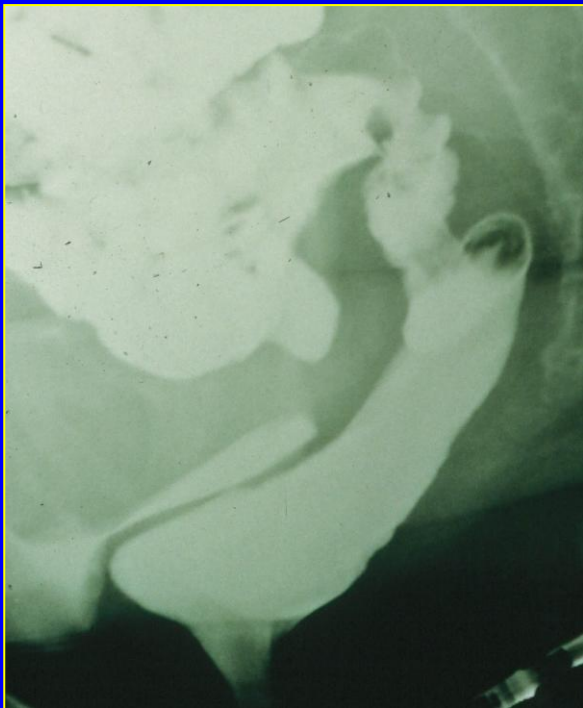

# Normaal

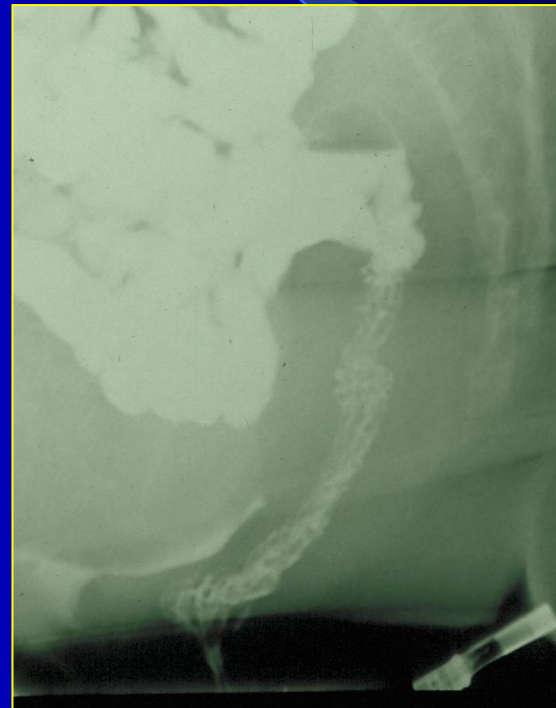

Rust

# Normaal

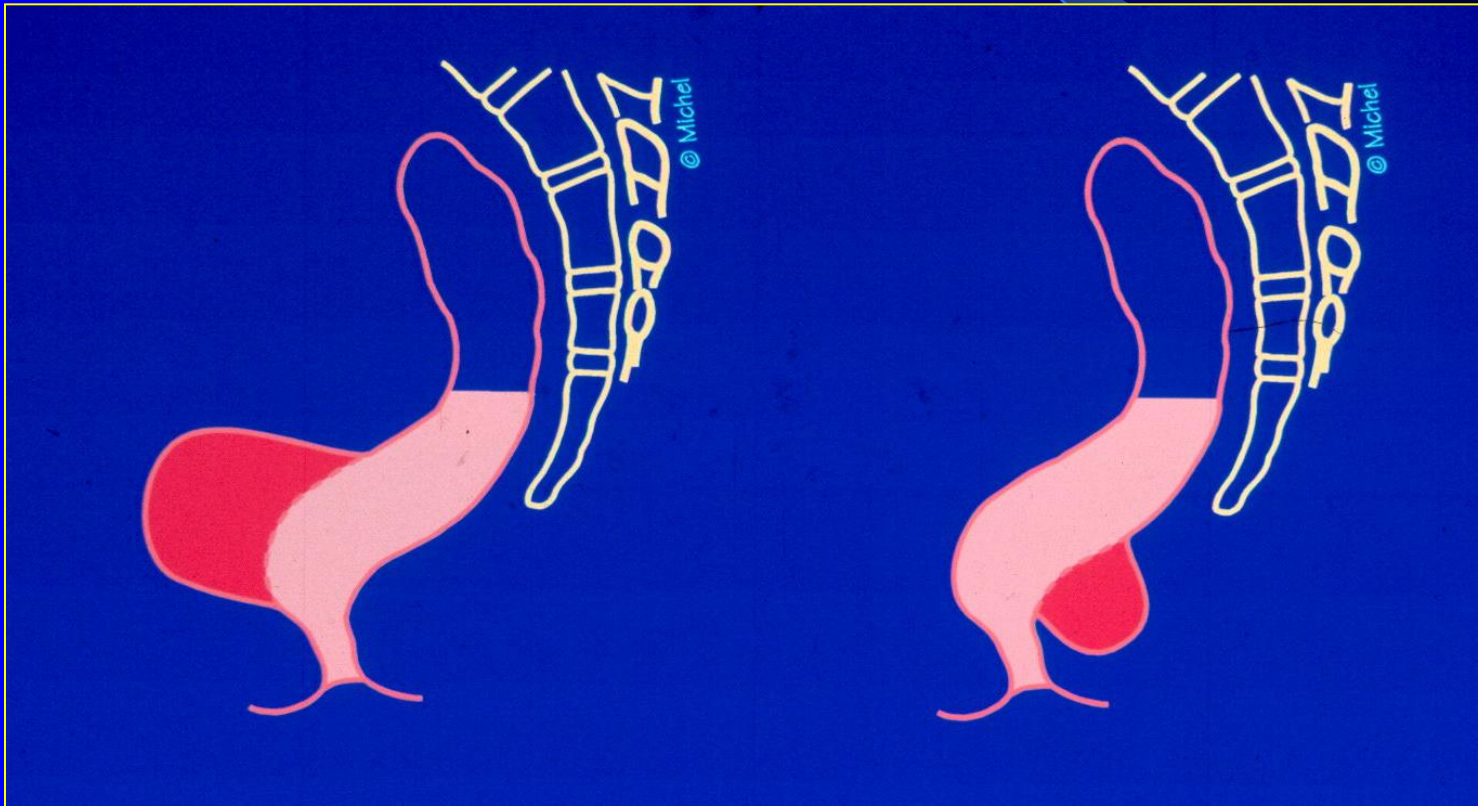


Defecatie

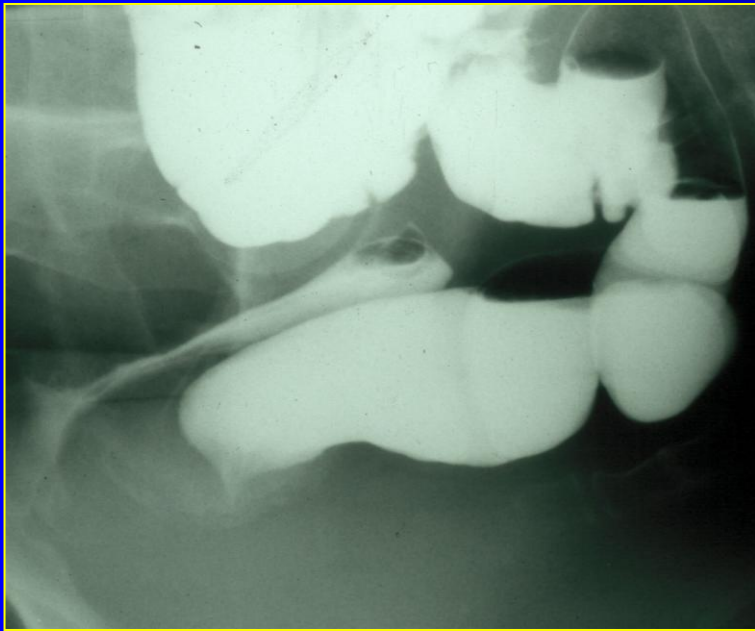


Post-defecatie

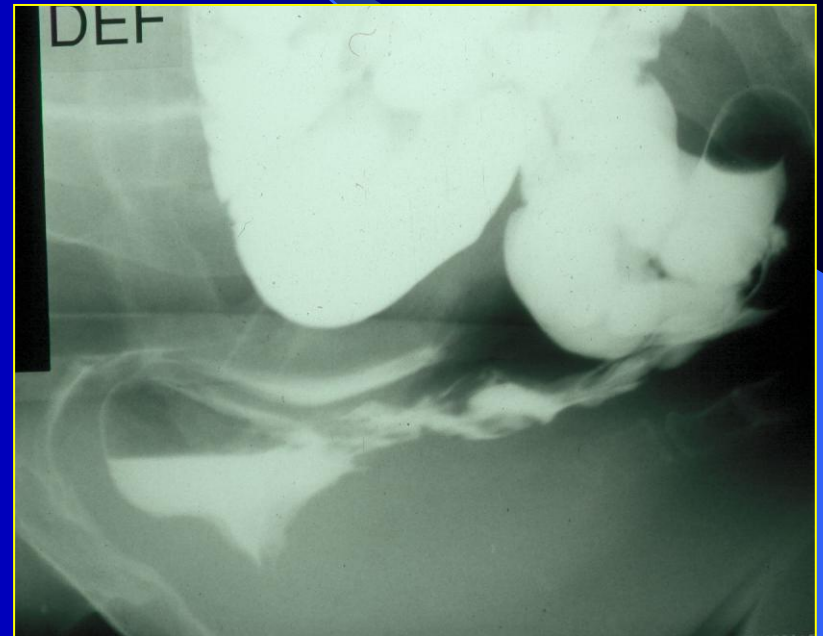
# Rectocele



# Rectocele



Rust



Defecatie

# Anteriore Rectocele

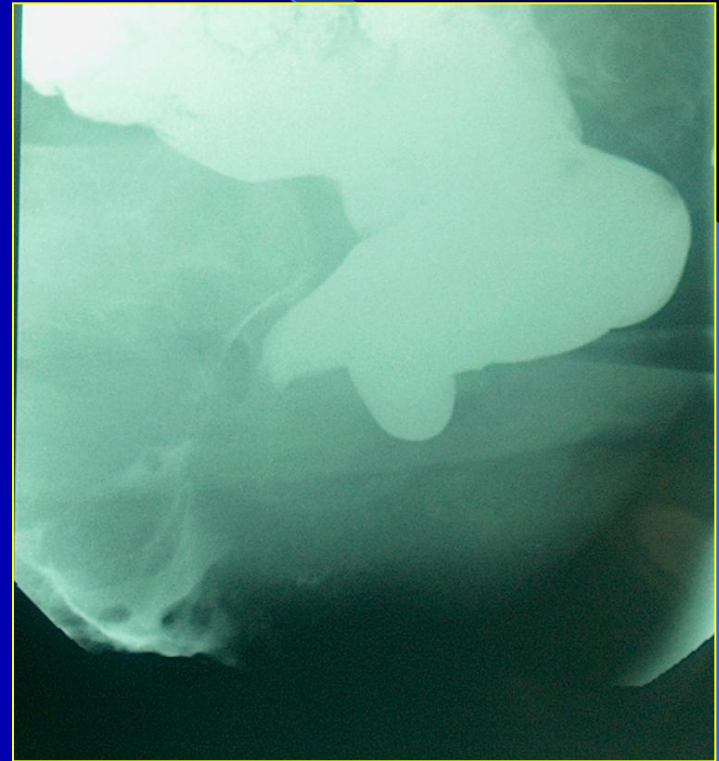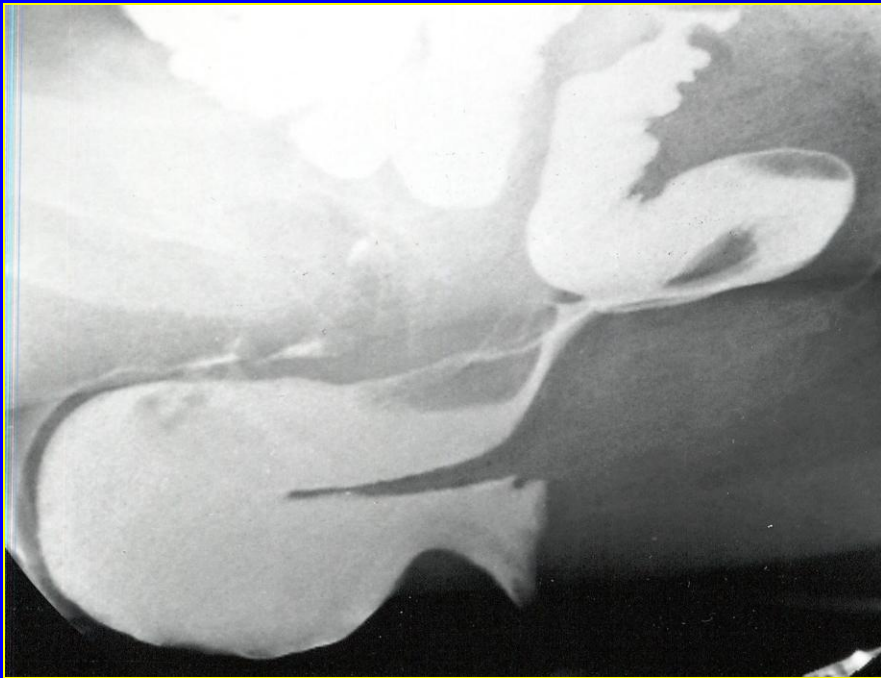Incidentie:

Vrouwelijke patiënten : 76 %

Vrouwen zonder klachten : 76 %



# Rectocele



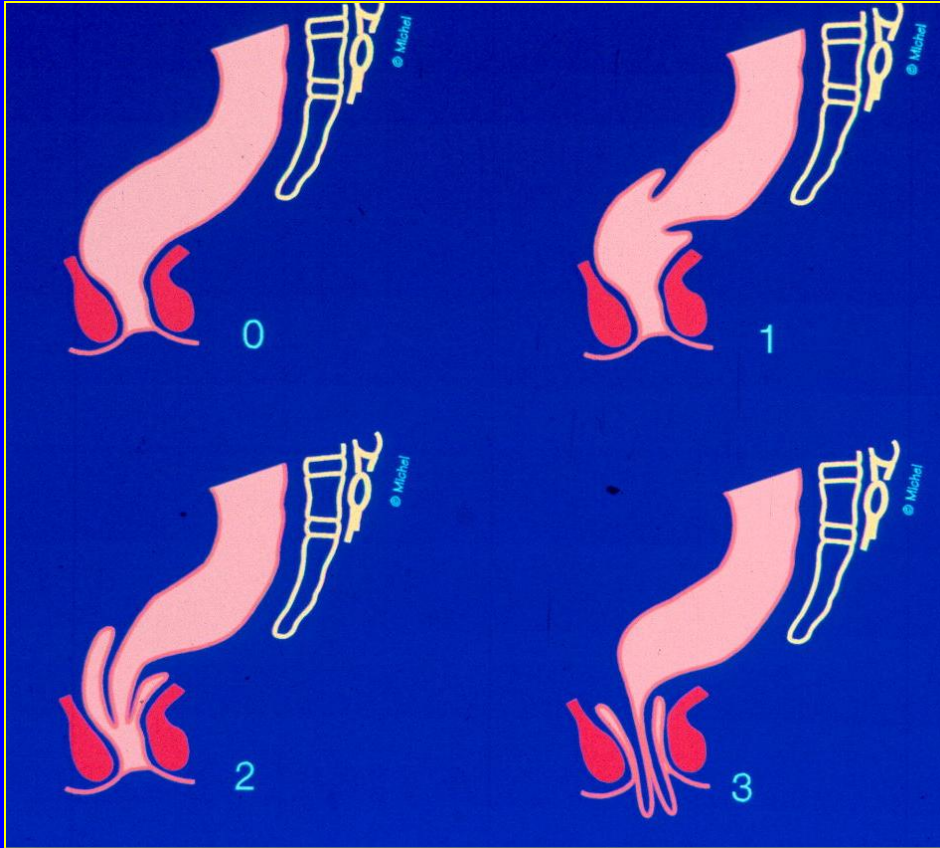


# Rectocele

Operatie indicatie:

- Digitale ondersteuning
- Problemen coïtus

# Intussusceptie



0: Geen intussusceptie

1: Intra-rectale intuss.

2: Intra-anale intuss.

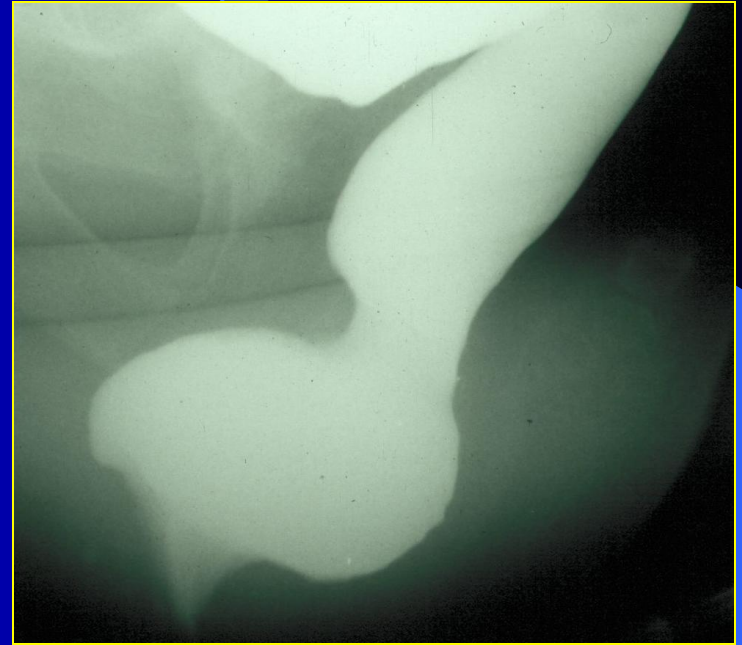
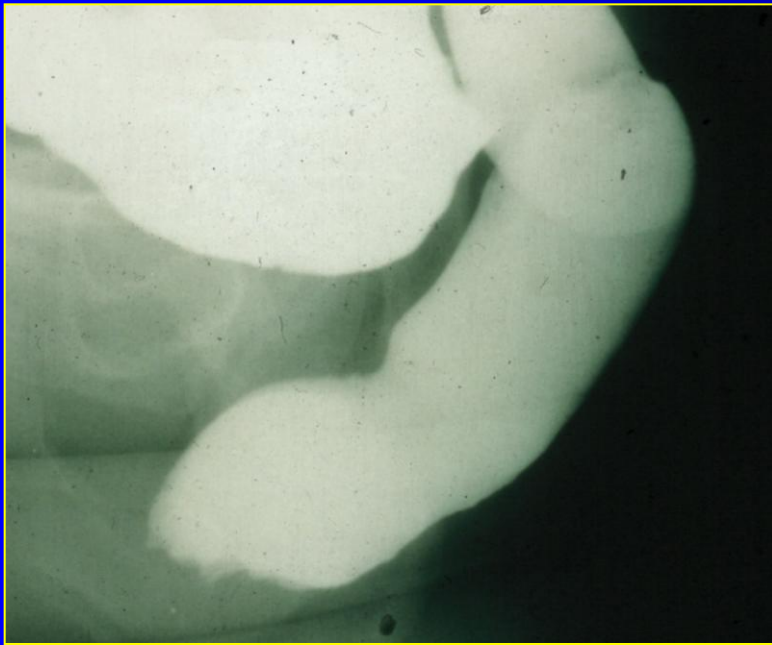
3: Extra-anale intuss.  
(Rectal prolapse)

# DRE

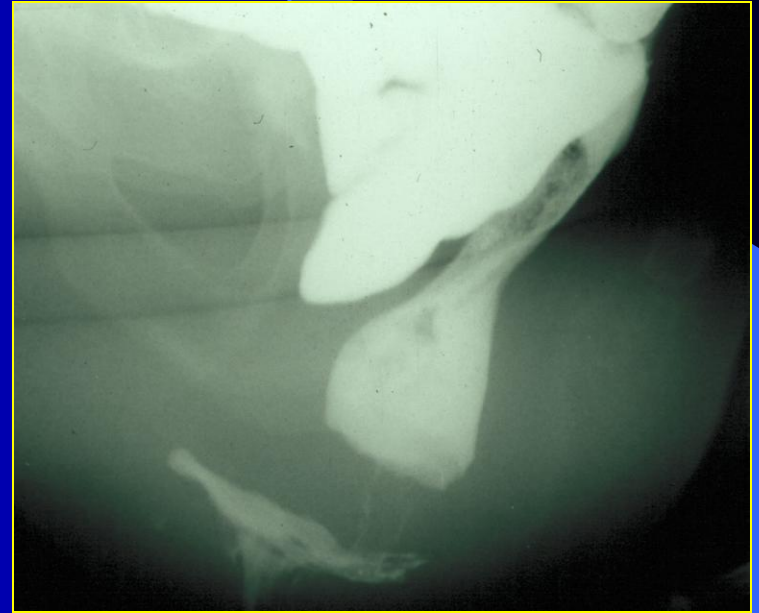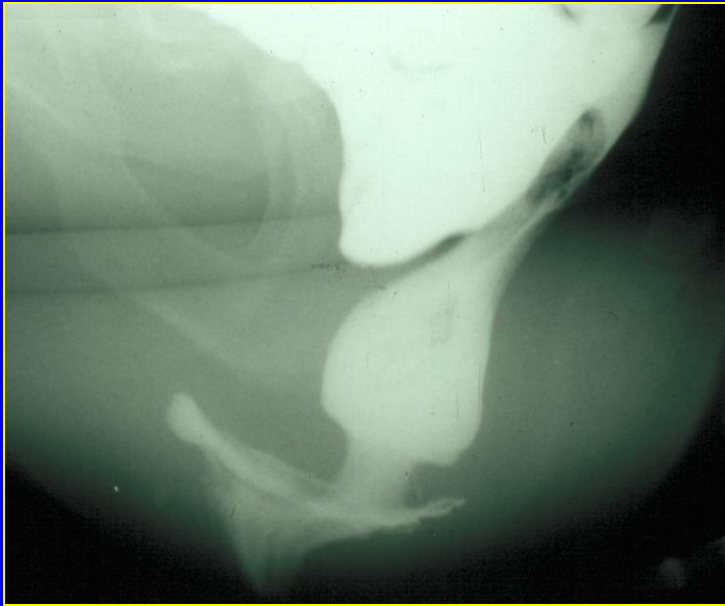
Lichamelijk onderzoek inadequaat bij  
diagnostiseren van intussuscepties

*Groenendijk et al  
Int Urogynecol J, 2008*

# Intussusceptie



# Intussusceptie



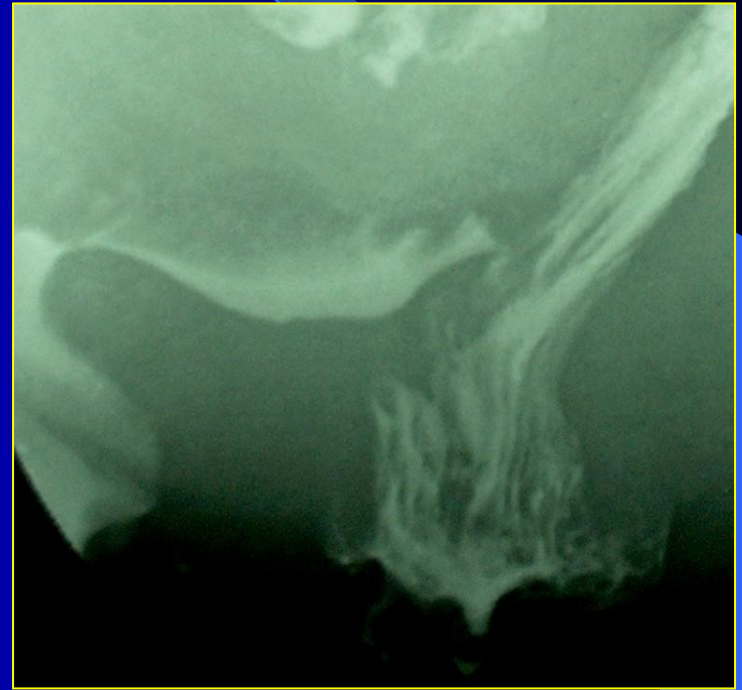
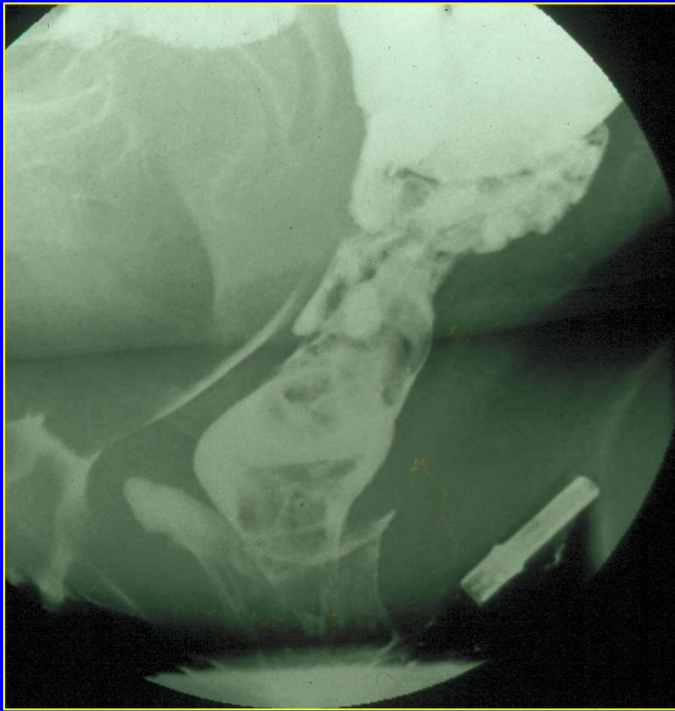
# Invloed Zwaartekracht

In verticale positie is de prolaps  
geprononceerder dan in horizontale houding

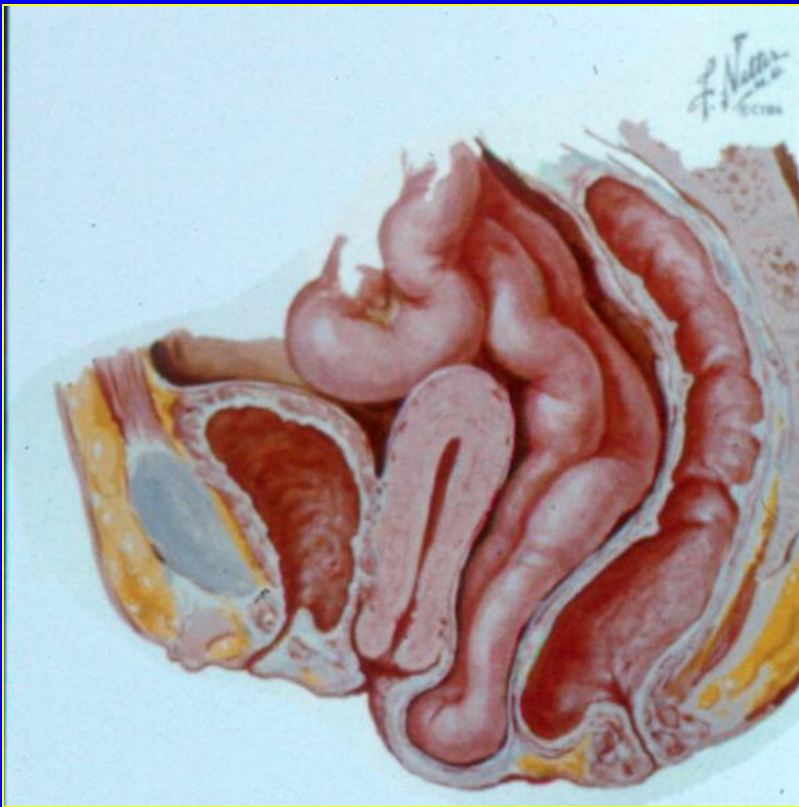
*Barber et al  
Obstet Gynecol, 2000*



# Intussusceptie versus mucosaprolapse



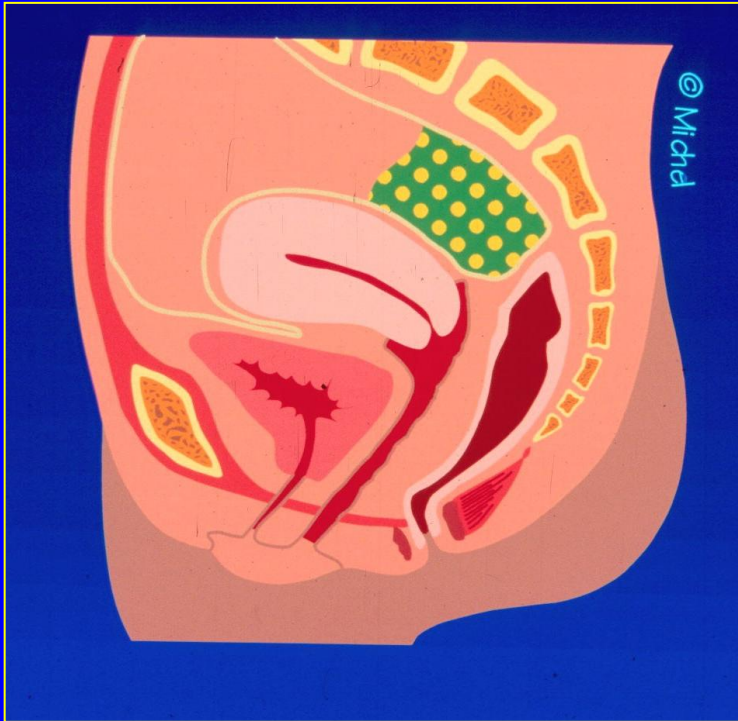
# Enterocele



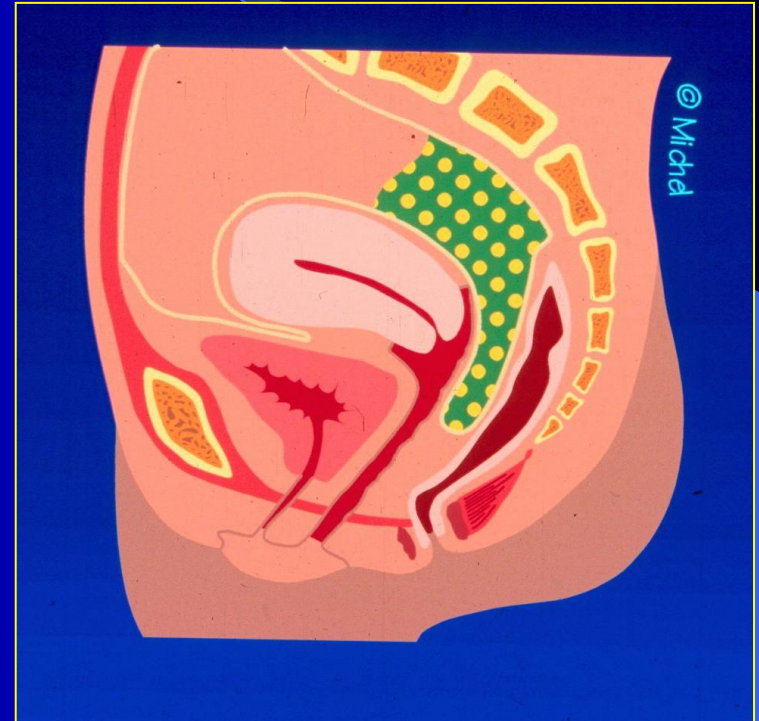
Definitie:

Peritoneale  
verzakking langs de  
rectumvoorwand

# Enterocele



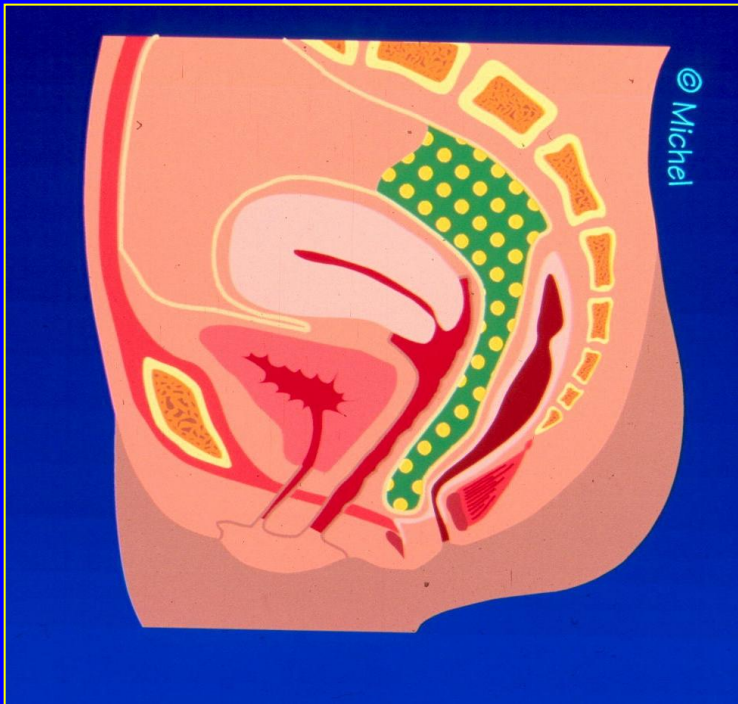
Geen Enterocele



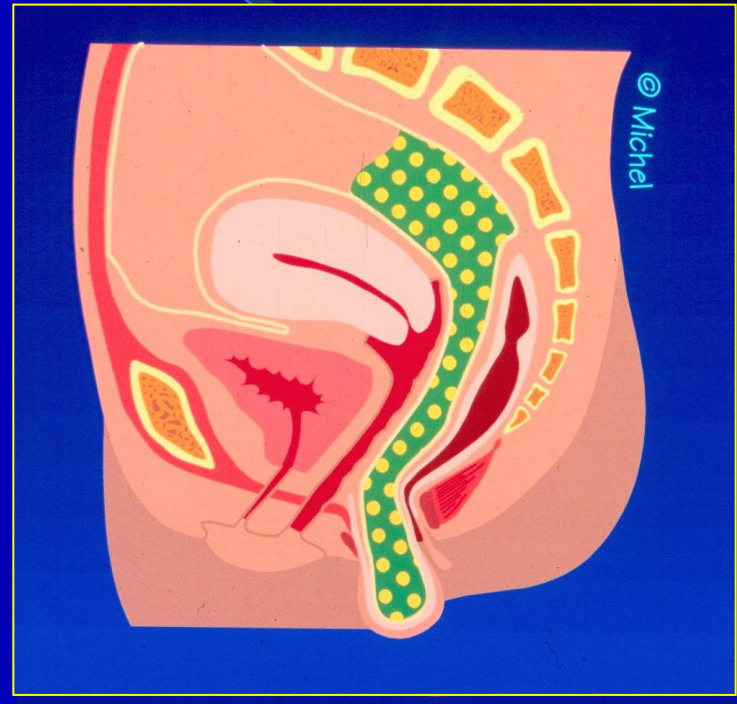
Graad 1



# Enterocele

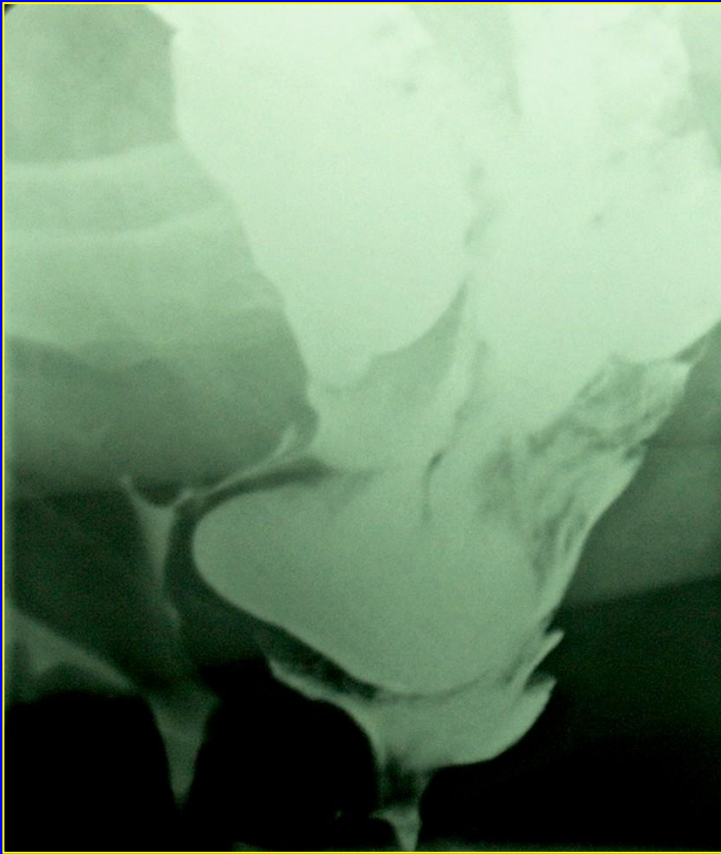


Graad 2

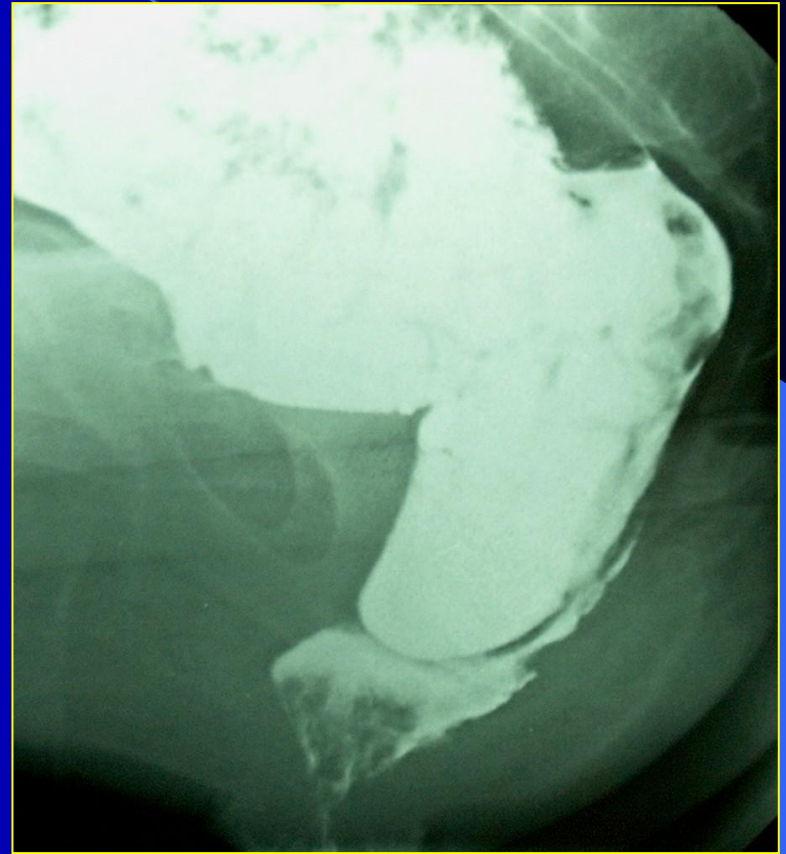


Graad 3

# Enterocele

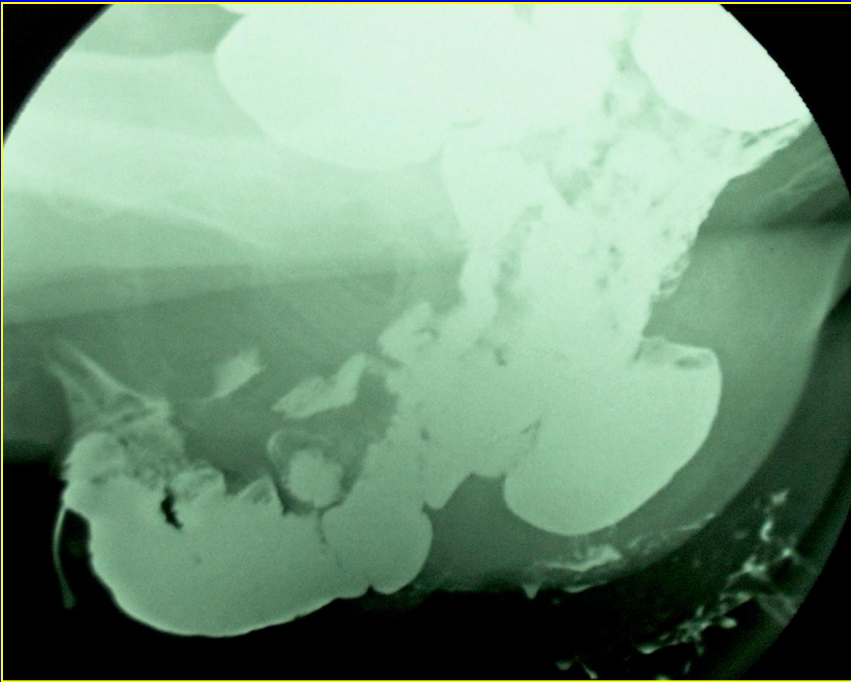


Graad 2 vrouw

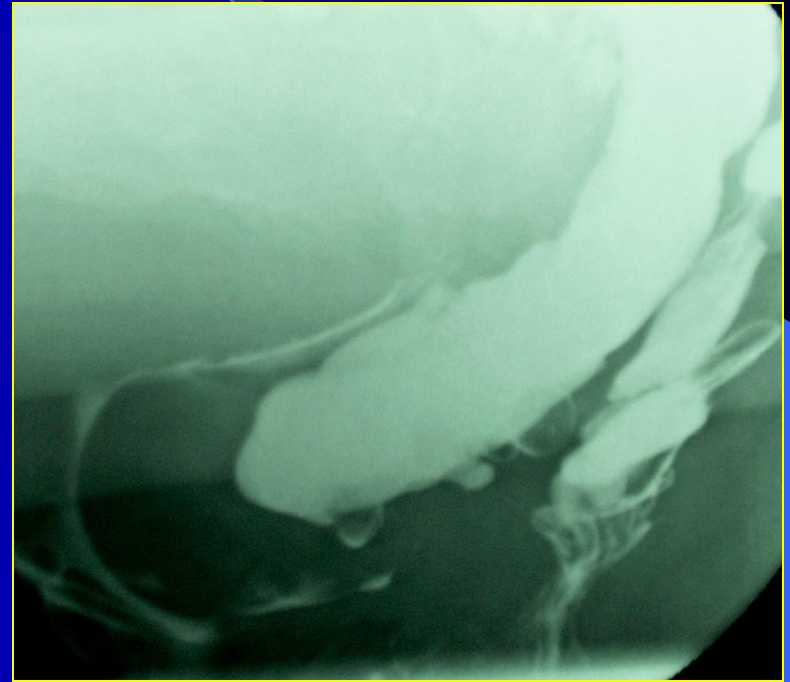

Graad 2 man

# Enterocele



Graad 3 vrouw



Sigmoidocele



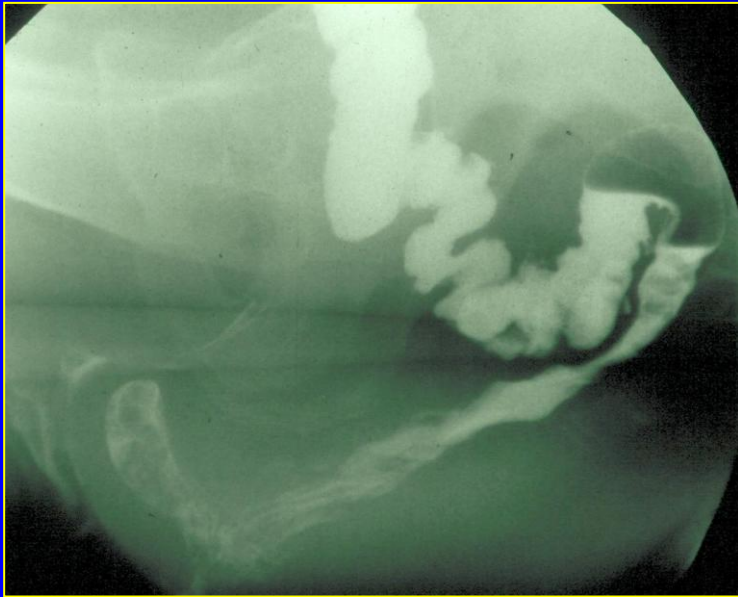
# Incidence enteroceles

- females:

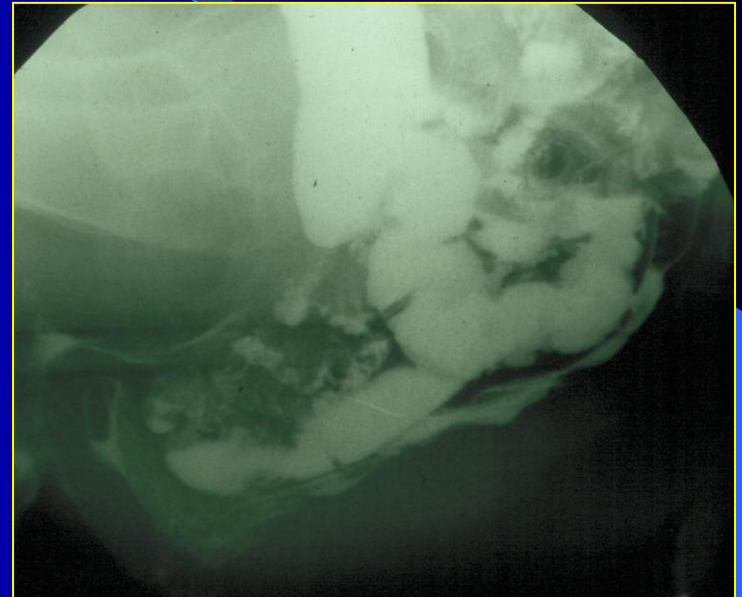
hysterectomy	22 %
without hysterectomy	9 %

(p = 0.0003)
- males: 5 %

# Enterocele

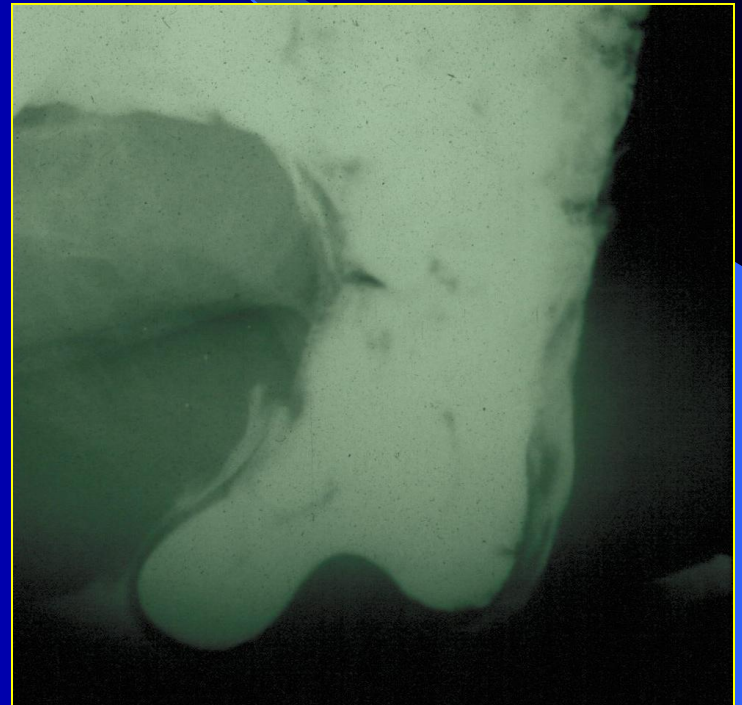
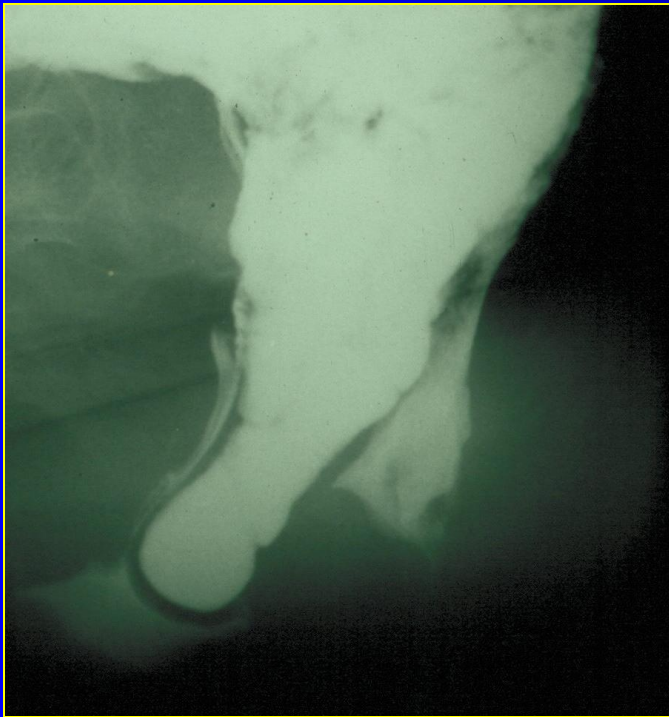


Zonder oraal contrast

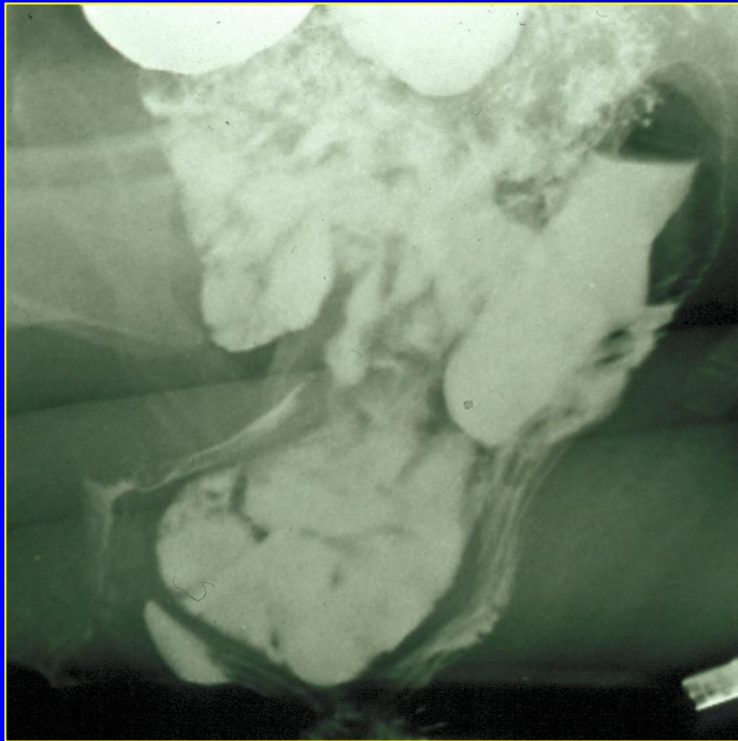


Met oraal contrast

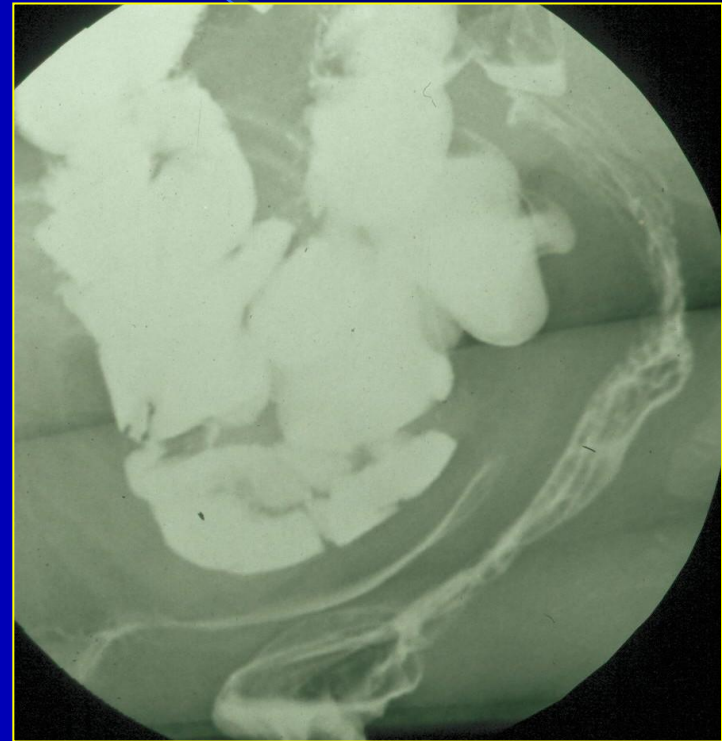
# Zadel-enterocele



# Enterocele

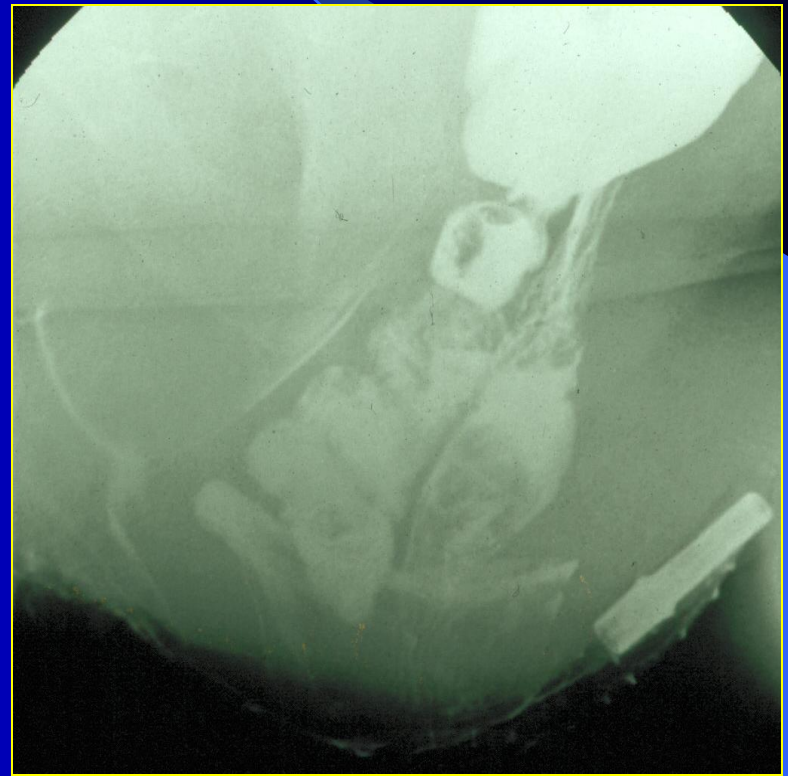
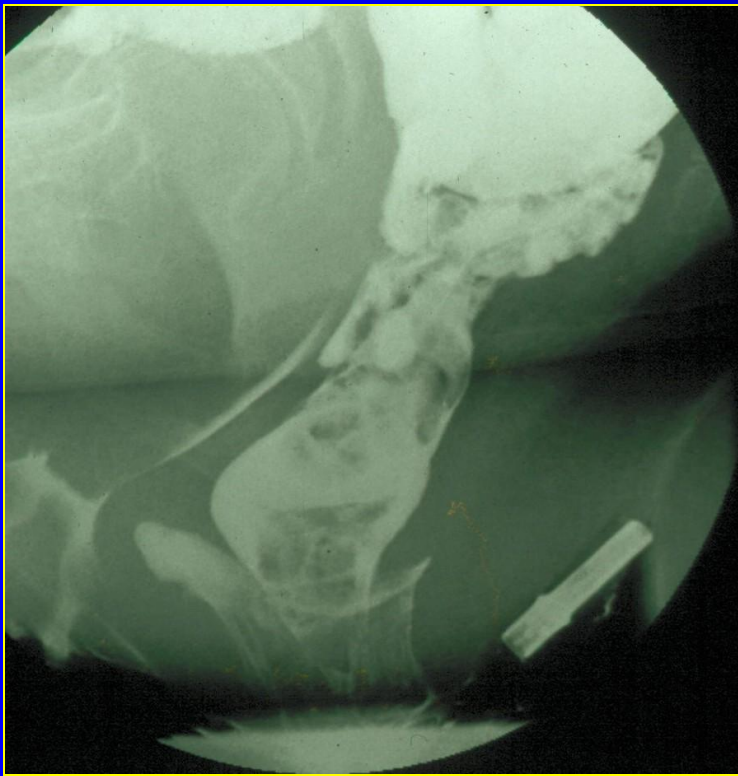


Pre-operatief



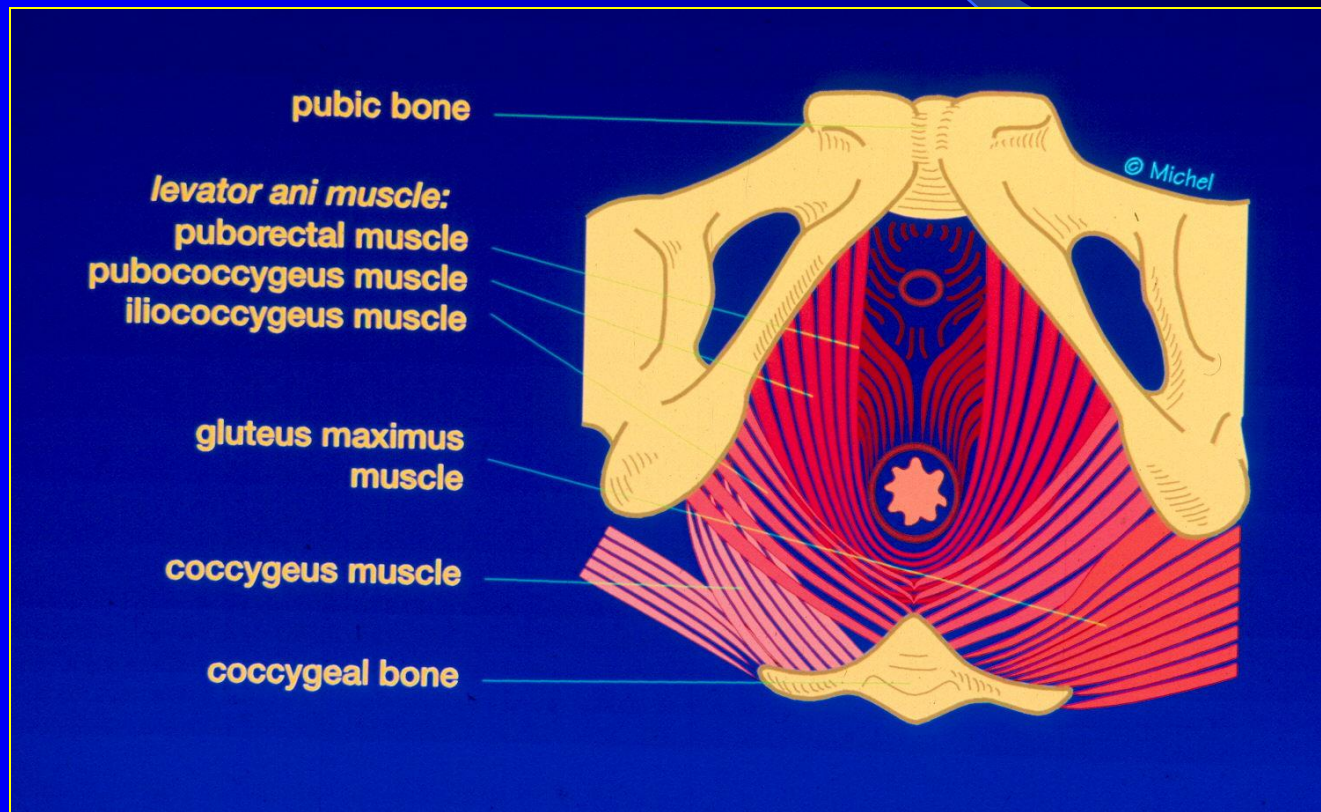
Post-operatief

# Enterocoele & intussusceptie



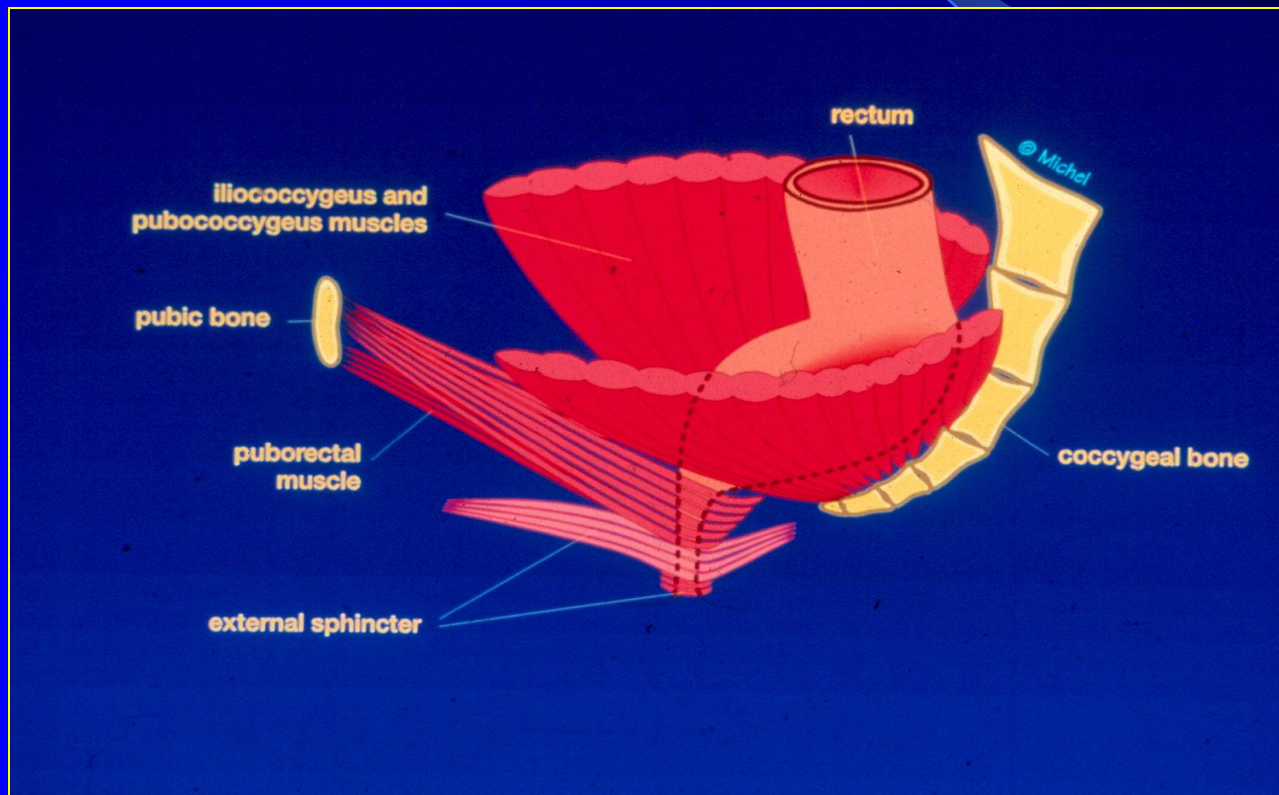


# Bekkenbodemmusculatuur

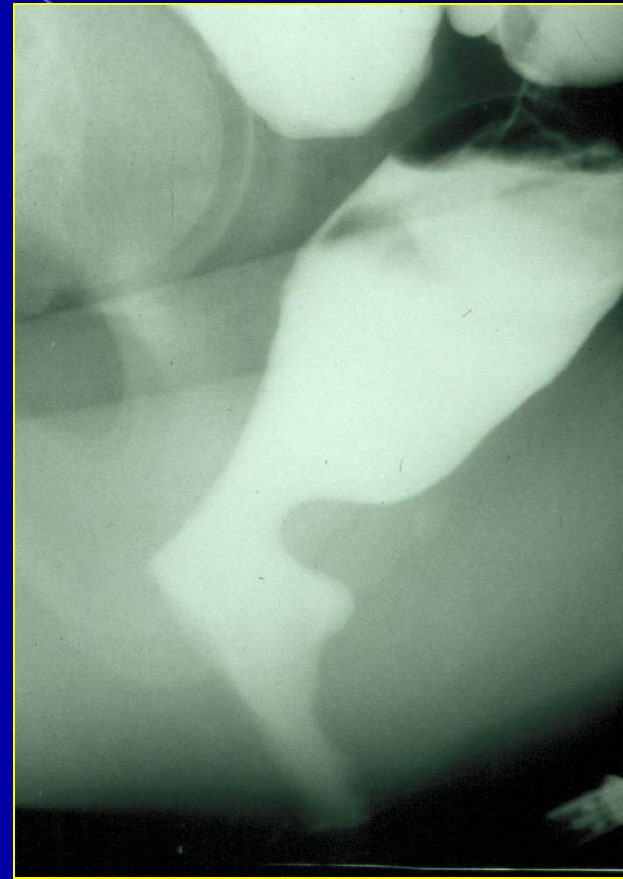
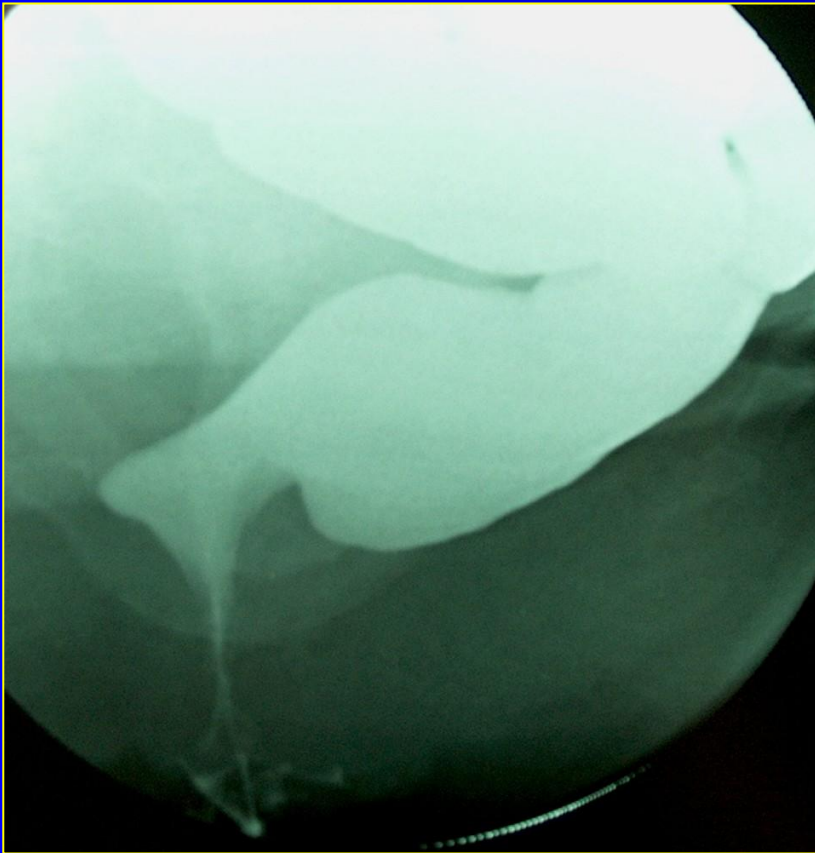




# Bekkenbodemmusculatuur



# Hypertone musculus puborectalis



# DRE

Diagnostische waarde voor  
differentiatie tussen:

enterocele en rectocele

*Altman et al*  
*Int Urogynecol J, 2005*

# DRE

Toegevoegde pré-operatieve waarde bij:  
posteriore vaginawand prolaps

*Groenendijk et al  
Int Urogynecol J, 2008*

# DRE

Betrouwbaarste diagnostisch onderzoek  
voor evaluatie van anorectum

*Maglinte et al  
Eur J Radiol, 2007*

# DRE

Anorectale hoekmeting : onzin

Meting perineale descent : onzin

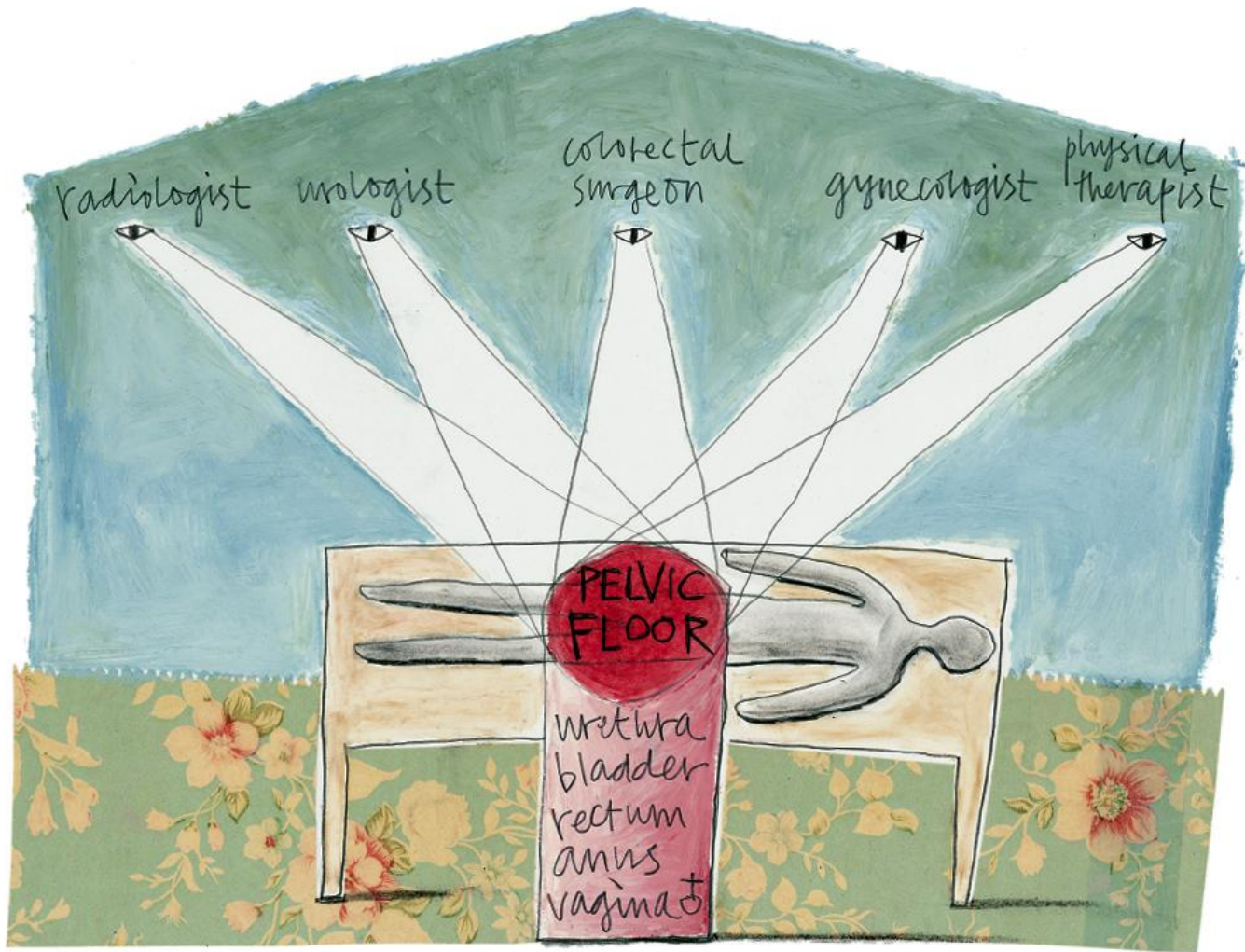


# Indications DRE

- interrupted/obstructed defecation
- fecal incontinence combined with obstructed defecation

# Contra-indicaties DRE

- darmperforatie
- (actieve) ontsteking



Referentie:

<http://www.radiologyassistant.nl>